

Newborn Skin: Part I. Common Rashes

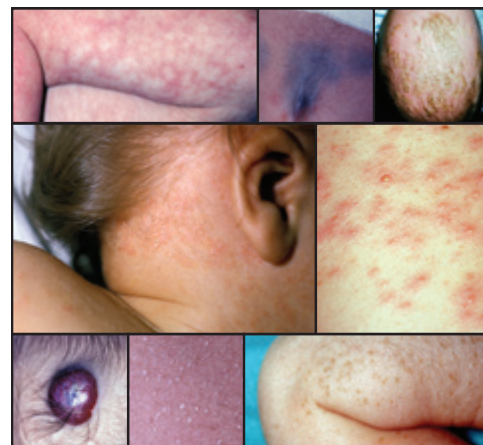NINA R. O'CONNOR, MD, *Chestnut Hill Hospital Family Practice Residency Program, Philadelphia, Pennsylvania*

MAURA R. McLAUGHLIN, MD, and PETER HAM, MD, *University of Virginia School of Medicine, Charlottesville, Virginia*

Rashes are extremely common in newborns and can be a significant source of parental concern. Although most rashes are transient and benign, some require additional work-up. Erythema toxicum neonatorum, acne neonatorum, and transient neonatal pustular melanosis are transient vesiculopustular rashes that can be diagnosed clinically based on their distinctive appearances. Infants with unusual presentations or signs of systemic illness should be evaluated for *Candida*, viral, and bacterial infections. Milia and miliaria result from immaturity of skin structures. Miliaria rubra (also known as heat rash) usually improves after cooling measures are taken. Seborrheic dermatitis is extremely common and should be distinguished from atopic dermatitis. Parental reassurance and observation is usually sufficient, but tar-containing shampoo, topical ketoconazole, or mild topical steroids may be needed to treat severe or persistent cases. (*Am Fam Physician*. 2008;77(1):47-52. Copyright © 2008 American Academy of Family Physicians.)

This is part I of a two-part article on newborn skin. Part II, "Birthmarks," appears in this issue of *AFP* on page 56.

A newborn's skin may exhibit a variety of changes during the first four weeks of life. Most of these changes are benign and self-limited, but others require further work-up for infectious etiologies or underlying systemic disorders. Nearly all of these skin changes are concerning to parents and may result in visits to the physician or questions during routine newborn examinations. Thus, physicians who care for



infants must be able to identify common skin lesions and counsel parents appropriately. Part I of this article reviews the presentation, prognosis, and treatment of the most common rashes that present during the first four weeks of life. Part II of this article, which appears in this issue of *AFP* (page 56), discusses the identification and management of birthmarks that appear in the neonatal period.¹

Transient Vascular Phenomena

Newborn vascular physiology is responsible for two types of transient skin color changes: cutis marmorata and harlequin color change. These transient vascular phenomena represent normal newborn physiology rather than actual skin rashes, but they often cause parental concern.

CUTIS MARMORATA

Cutis marmorata is a reticulated mottling of the skin that symmetrically involves the trunk and extremities (*Figure 1*). It is caused by a vascular response to cold and generally resolves when the skin is warmed. A tendency to cutis marmorata may persist for several weeks or months, or sometimes into early childhood.² No treatment is indicated.

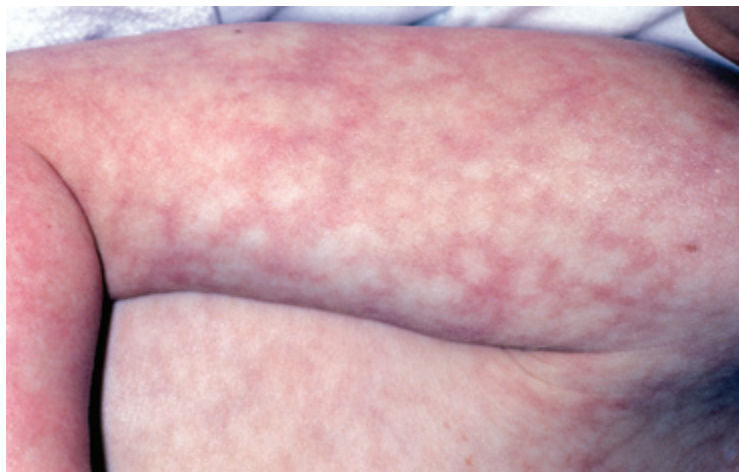


Figure 1. Cutis marmorata, a normal reticulated mottling of the skin caused by vascular response to cold.

SORT: KEY RECOMMENDATIONS FOR PRACTICE

Clinical recommendation	Evidence rating	References
Infants who appear sick and have vesiculopustular rashes should be tested for <i>Candida</i> , viral, and bacterial infections.	C	7, 8
Acne neonatorum usually resolves within four months without scarring. In severe cases, 2.5% benzoyl peroxide lotion can be used to hasten resolution.	C	10
Miliaria rubra (also known as heat rash) responds to avoidance of overheating, removal of excess clothing, cool baths, and air conditioning.	C	6
Infantile seborrheic dermatitis usually responds to conservative treatment, including petrolatum, soft brushes, and tar-containing shampoo.	C	13
Resistant seborrheic dermatitis can be treated with topical antifungals or mild corticosteroids.	B	17-19

A = consistent, good-quality patient-oriented evidence; B = inconsistent or limited-quality patient-oriented evidence; C = consensus, disease-oriented evidence, usual practice, expert opinion, or case series. For information about the SORT evidence rating system, see <http://www.aafp.org/afpsort.xml>.

HARLEQUIN COLOR CHANGE

Harlequin color change occurs when the newborn lies on his or her side. It consists of erythema of the dependent side of the body with simultaneous blanching of the contralateral side. The color change develops suddenly and persists for 30 seconds to 20 minutes. It resolves with increased muscle activity or crying. This phenomenon affects up to 10 percent of full-term infants, but it often goes unnoticed because the infant is bundled.³ It occurs most commonly during the second to fifth day of life and may continue for up to three weeks. Harlequin color change is thought to be caused by immaturity of the hypothalamic center that controls the dilation of peripheral blood vessels.

Erythema Toxicum Neonatorum

Erythema toxicum neonatorum is the most common pustular eruption in newborns. Estimates of incidence vary between 40 and 70 percent.⁴ It is most common in infants born at term and weighing more than 2,500 g (5.5 lb).⁵ Erythema toxicum neonatorum may be present at birth but more often appears during the second or third day of life. Typical lesions consist of erythematous, 2- to 3-mm macules and papules that evolve into pustules⁶ (Figure 2). Each pustule is surrounded by a blotchy area of erythema, leading to what is classically described as a “flea-bitten” appearance. Lesions usually occur on the face, trunk, and proximal extremities. Palms and soles are not involved.

Several infections (e.g., herpes simplex, *Candida*, and *Staphylococcus* infections) also may present with vesiculopustular rashes in the neonatal period (Table 1)^{6,7}; infants who appear sick or who have an atypical rash should be tested for these infections.⁸ In healthy infants, the diagnosis of erythema toxicum neonatorum is made clinically and can be confirmed by cytologic examination of a pustular smear, which will show eosinophilia with Gram, Wright, or Giemsa staining. Peripheral eosinophilia may also be present.⁷

The etiology of erythema toxicum neonatorum is not known. Lesions generally fade over five to seven days, but they may recur for several weeks. No treatment is needed, and the condition is not associated with any systemic abnormality.

Transient Neonatal Pustular Melanosis

Transient neonatal pustular melanosis is a vesiculopustular rash that occurs in 5 percent of black newborns, but in less than 1 percent of white newborns.^{6,9} In contrast with erythema toxicum neonatorum, the lesions of transient neonatal pustular melanosis lack surrounding erythema (Figure 3). In addition, these lesions rupture easily, leaving a collarette of scale and a pigmented macule that fades over three to four weeks. All areas of the body may be affected, including palms and soles.

Clinical recognition of transient neonatal pustular melanosis can help physicians avoid unnecessary diagnostic testing and treatment for infectious etiologies.

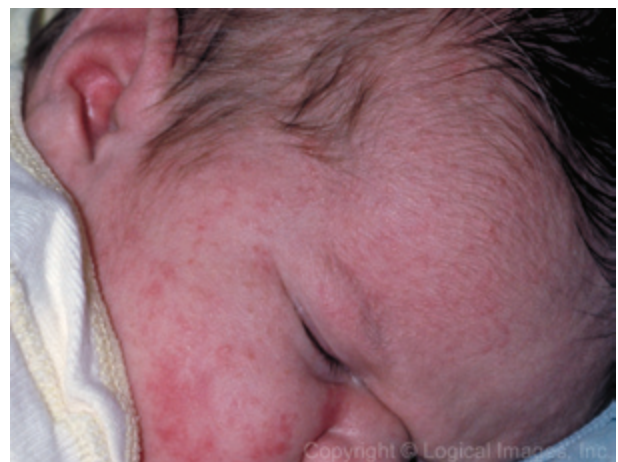

Figure 2. Erythema toxicum neonatorum can result in a “flea-bitten” appearance.

Copyright © Logical Images, Inc.

Table 1. Infectious Causes of Vesicles or Pustules in the Newborn

Class	Cause	Distinguishing features
Bacterial	Group A or B <i>Streptococcus</i> <i>Listeria monocytogenes</i> <i>Pseudomonas aeruginosa</i> <i>Staphylococcus aureus</i> Other gram-negative organisms	Other signs of sepsis usually present Elevated band count, positive blood culture; Gram stain of intralesional contents shows polymorphic neutrophils
Fungal	<i>Candida</i>	Presents within 24 hours after birth if congenital, after one week if acquired during delivery Thrush is common Potassium hydroxide preparation of intralesional contents shows pseudohyphae and spores
Spirochetal	Syphilis	Rare Lesions on palms and soles Suspect if results of maternal rapid plasma reagin or venereal disease research laboratory test positive or unknown
Viral	Cytomegalovirus Herpes simplex Varicella zoster	Crops of vesicles and pustules appear on erythematous base For herpes simplex and varicella zoster, Tzanck test of intralesional contents shows multinucleated giant cells

Information from references 6 and 7.

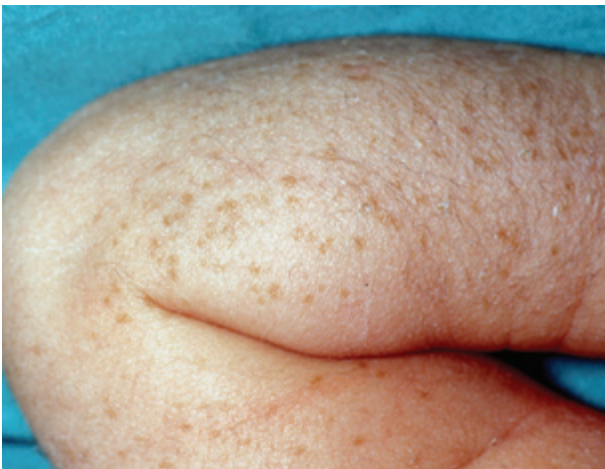


Figure 3. Transient neonatal pustular melanosis results in pigmented macules that gradually fade over several weeks.

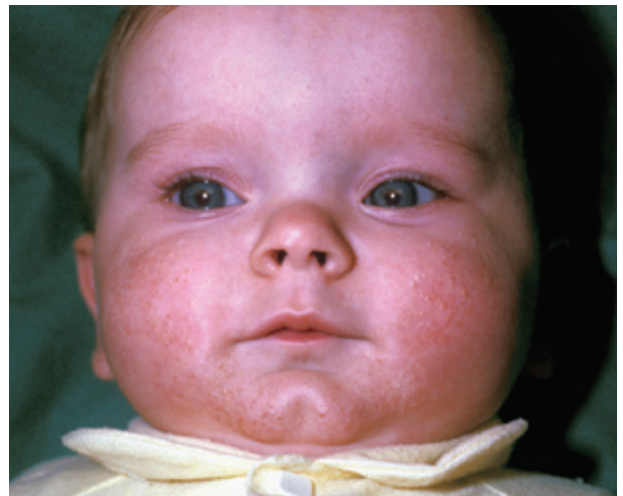

Figure 4. Acne neonatorum typically consists of closed comedones on the forehead, nose, and cheeks.

The pigmented macules within the vesicopustules are unique to this condition; these macules do not occur in any of the infectious rashes.⁹ Gram, Wright, or Giemsa staining of the pustular contents will show polymorphic neutrophils and, occasionally, eosinophils.

Acne Neonatorum

Acne neonatorum occurs in up to 20 percent of newborns¹⁰ (Figure 4). It typically consists of closed comedones on the forehead, nose, and cheeks, although other locations are possible. Open comedones, inflammatory papules, and pustules can also develop.

Neonatal acne is thought to result from stimulation of sebaceous glands by maternal or infant androgens. Parents should be counseled that lesions usually resolve spontaneously within four months without scarring. Treatment generally is not indicated, but infants can be treated with a 2.5% benzoyl peroxide lotion if lesions are extensive and persist for several months.⁷ Parents should apply a small amount of benzoyl peroxide to the antecubital fossa to test for local reaction before widespread or facial application. Severe, unrelenting neonatal acne accompanied by other signs of hyperandrogenism should prompt an investigation for adrenal

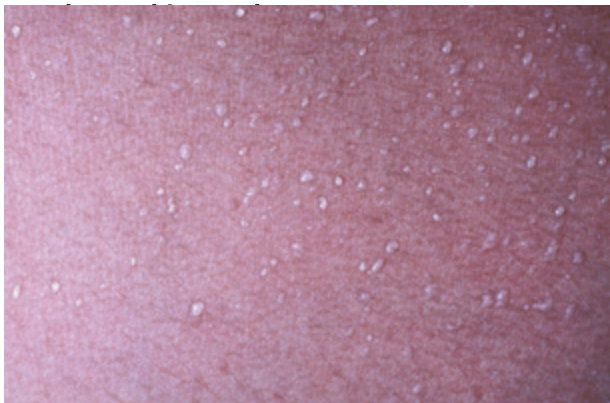

Figure 5. Miliaria crystallina consists of 1- to 2-mm vesicles without surrounding erythema. It most commonly occurs on the head, neck, and trunk.

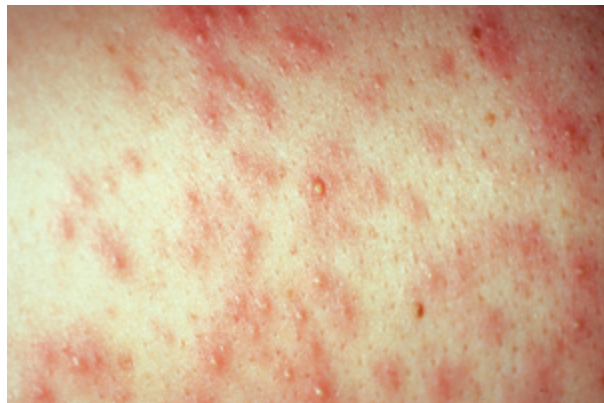

Figure 6. Miliaria rubra, also known as heat rash, consists of small erythematous papules and vesicles on covered portions of the skin.

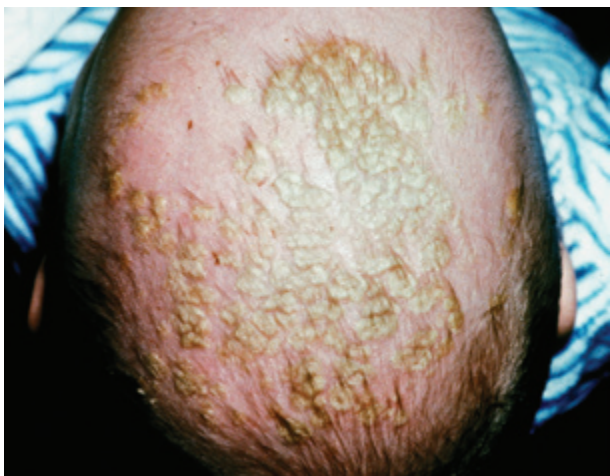


Figure 7. Infantile seborrheic dermatitis is commonly called "cradle cap" when it occurs on the scalp.

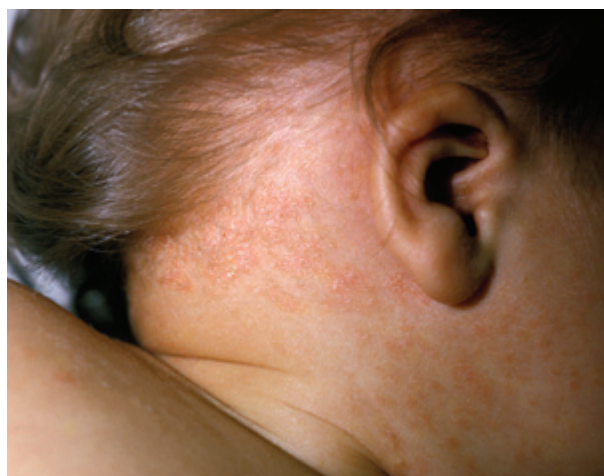

Figure 8. Seborrheic dermatitis can affect the scalp, face, ears, neck, and diaper area.

cortical hyperplasia, virilizing tumors, or underlying endocrinopathies.¹⁰

Milia

Milia are 1- to 2-mm pearly white or yellow papules caused by retention of keratin within the dermis. They occur in up to 50 percent of newborns.¹¹ Milia occur most often on the forehead, cheeks, nose, and chin, but they may also occur on the upper trunk, limbs, penis, or mucous membranes. Milia disappear spontaneously, usually within the first month of life, although they may persist into the second or third month.¹¹ Milia are a common source of parental concern, and simple reassurance about their benign, self-limited course is appropriate.

Miliaria

Miliaria results from sweat retention caused by partial closure of eccrine structures. Both milia and miliaria result from immaturity of skin structures, but they are clinically distinct entities. Miliaria affects up to 40 percent of infants and usually appears during the first

month of life.¹² Several clinically distinguishable subtypes exist; miliaria crystallina and miliaria rubra are the most common.

Miliaria crystallina is caused by superficial eccrine duct closure. It consists of 1- to 2-mm vesicles without surrounding erythema, most commonly on the head, neck, and trunk (*Figure 5*). Each vesicle evolves, with rupture followed by desquamation, and may persist for hours to days.

Miliaria rubra, also known as heat rash, is caused by a deeper level of sweat gland obstruction (*Figure 6*). Its lesions are small erythematous papules and vesicles, usually occurring on covered portions of the skin. Miliaria crystallina and miliaria rubra are benign. Avoidance of overheating, removal of excess clothing, cooling baths, and air conditioning are recommended for management and prevention of these disorders.⁶

Seborrheic Dermatitis

Seborrheic dermatitis is an extremely common rash characterized by erythema and greasy scales (*Figures 7 and 8*).

Many parents know this rash as “cradle cap” because it occurs most commonly on the scalp. Other affected areas may include the face, ears, and neck. Erythema tends to predominate in the flexural folds and intertriginous areas, whereas scaling predominates on the scalp.¹³ Because seborrheic dermatitis often spreads to the diaper area, it is important to consider in the evaluation of diaper dermatitis.¹⁴

Seborrheic dermatitis can be difficult to clinically distinguish from atopic dermatitis, but age at onset and the presence or absence of pruritus can be helpful (Table 2).¹⁴ Psoriasis also has a clinical appearance similar to that of seborrheic dermatitis, but it is less common.

The exact etiology of seborrheic dermatitis is unknown. Some studies have implicated the yeast *Malassezia furfur* (previously known as *Pityrosporum ovale*).¹⁵ Hormonal fluctuations may also be involved, which would explain why seborrheic dermatitis occurs most often in areas with a high density of sebaceous glands. Generalized seborrheic dermatitis accompanied by failure to thrive and diarrhea should prompt an evaluation for immunodeficiency.¹³

Infantile seborrheic dermatitis is usually self-limited, resolving within several weeks to several months. In one prospective study, children with infantile seborrheic dermatitis were reexamined 10 years later.¹⁶

Table 2. Distinguishing Features of Seborrheic and Atopic Dermatitis in Infancy

Feature	Seborrheic dermatitis	Atopic dermatitis
Age at onset	Usually within first month	After three months of age
Course	Self-limited, responds to treatment	Responds to treatment, but frequently relapses
Distribution	Scalp, face, ears, neck, diaper area	Scalp, face, trunk, extremities, diaper area
Pruritus	Uncommon	Ubiquitous

Adapted with permission from Williams ML. Differential diagnosis of seborrheic dermatitis. Pediatr Rev. 1986;7(7):205.

Overall, 85 percent of children were free of skin disease at follow-up. Seborrheic dermatitis persisted in 8 percent of children, but the link between infantile and adult seborrheic dermatitis remains unclear. In addition, 6 percent of children in this study later were diagnosed with atopic dermatitis, illustrating the difficulty in distinguishing these conditions during infancy.

Given the benign, self-limited nature of seborrheic dermatitis in infants, a conservative stepwise approach to treatment is warranted. Physicians should begin with reassurance and watchful waiting. If cosmesis is a concern, scales can often be removed with a soft brush after shampooing. An emollient, such as white petrolatum,

Table 3. Treatment Options for Infantile Seborrheic Dermatitis

Medication	Directions	Cost (generic)*	Notes
White petrolatum	Apply daily	\$3 for 30 g	May soften scales, facilitating removal with soft brush
Tar-containing shampoo	Use several times per week	\$13 to \$15 for 240 mL	Use when baby shampoo has failed Safe, but potentially irritating
Ketoconazole (Nizoral, brand no longer available in the United States), 2% cream or 2% shampoo	Cream: apply to scalp three times weekly Shampoo: lather, leave on for three minutes, then rinse. Use three times weekly	Cream: (\$16 to \$37 for 15 g) Shampoo: \$30 to \$33 for 120 mL (\$16 to \$38)	Small trial showed no systemic drug levels or change in liver function after one month of use
Hydrocortisone 1% cream	Apply every other day or daily	\$2 to \$4 for 30 g	Limit surface area to reduce risk of systemic absorption and adrenal suppression May be especially effective for rash in flexural areas

*—Estimated cost to the pharmacist based on average wholesale prices (rounded to the nearest dollar) in Red Book. Montvale, N.J.: Medical Economics Data, 2007. Cost to the patient will be higher, depending on prescription filling fee.

Information from references 13 and 17-19.

Newborn Skin: Rashes

may help soften the scales. Soaking the scalp overnight with vegetable oil and then shampooing in the morning is also effective.

If seborrheic dermatitis persists despite a period of watchful waiting, several treatment options exist (Table 3).^{13,17-19} Tar-containing shampoos can be recommended as first-line treatment.¹³ Selenium sulfide shampoos are probably safe, but rigorous safety data in infants is lacking. The use of salicylic acid is not recommended because of concerns about systemic absorption.¹³

Evidence from small randomized controlled trials supports the use of topical antifungal creams or shampoos if treatment with tar-containing shampoo fails.^{17,20} Mild steroid creams are another commonly prescribed option. One meta-analysis found that topical ketoconazole (Nizoral, brand no longer available in the United States) and steroid creams are effective in the treatment of infantile seborrheic dermatitis, but ketoconazole may be better at preventing recurrences.¹⁸

Figures 1 and 3 through 8 provided by Kenneth Greer, MD.

The authors thank Karen Knight, MSLS, for assistance with the literature search.

The Authors

NINA R. O'CONNOR, MD, is a faculty physician at Chestnut Hill Hospital Family Practice Residency Program in Philadelphia, Pa. She received her medical degree from the University of Virginia School of Medicine, Charlottesville, where she also completed a family medicine residency and a faculty development fellowship.

MAURA R. McLAUGHLIN, MD, is an assistant professor of family medicine at the University of Virginia School of Medicine. She received her medical degree from Loyola University Chicago (Ill.) Stritch School of Medicine and completed a family medicine residency at the University of Virginia School of Medicine.

PETER HAM, MD, is an assistant professor of family medicine at the University of Virginia School of Medicine, where he received his medical degree and completed a family medicine residency.

Address correspondence to Peter Ham, MD, University of Virginia School of Medicine, Dept. of Family Medicine, P.O. Box 800729 HSC, Charlottesville, VA 22908 (e-mail: ph2t@virginia.edu). Reprints are not available from the authors.

Author disclosure: Nothing to disclose.

REFERENCES

1. McLaughlin MR, O'Connor NR, Ham P. Newborn skin: part II. Birthmarks. *Am Fam Physician*. 2008;77(1):56-60.
2. Mazereeuw-Hautier J, Carel-Caneppele S, Bonafé JL. Cutis marmorata telangiectatica congenita: report of two persistent cases. *Pediatr Dermatol*. 2002;19(6):506-509.
3. Selimoglu MA, Dilmen U, Karakelleoglu C, Bitlisli H, Tunnessen WW. Picture of the month. Harlequin color change. *Arch Pediatr Adolesc Med*. 1995;149(10):1171-1172.
4. Liu C, Feng J, Qu R, et al. Epidemiologic study of the predisposing factors in erythema toxicum neonatorum. *Dermatology*. 2005;210(4):269-272.
5. Carr JA, Hodgman JE, Freedman RI, Levan NE. Relationship between toxic erythema and infant maturity. *Am J Dis Child*. 1966;112(2):129-134.
6. Schachner L, Press S. Vesicular, bullous and pustular disorders in infancy and childhood. *Pediatr Clin North Am*. 1983;30(4):609-629.
7. Van Praag MC, Van Rooij RW, Folkers E, Spritzer R, Menke HE, Oranje AP. Diagnosis and treatment of pustular disorders in the neonate. *Pediatr Dermatol*. 1997;14(2):131-143.
8. Chang MW, Jiang SB, Orlow SJ. Atypical erythema toxicum neonatorum of delayed onset in a term infant. *Pediatr Dermatol*. 1999;16(2):137-141.
9. Laude TA. Approach to dermatologic disorders in black children. *Semin Dermatol*. 1995;14(1):15-20.
10. Katsambas AD, Katoulis AC, Stavropoulos P. Acne neonatorum: a study of 22 cases. *Int J Dermatol*. 1999;38(2):128-130.
11. Paller A, Mancini AJ, Hurwitz S. *Hurwitz Clinical Pediatric Dermatology: A Textbook of Skin Disorders of Childhood and Adolescence*. 3rd ed. Philadelphia, Pa.: Elsevier Saunders, 2006:737.
12. Feng E, Janniger CK. Miliaria. *Cutis*. 1995;55(4):213-216.
13. Janniger CK. Infantile seborrheic dermatitis: an approach to cradle cap. *Cutis*. 1993;51(4):233-235.
14. Williams ML. Differential diagnosis of seborrheic dermatitis. *Pediatr Rev*. 1986;7(7):204-211.
15. Tolleson A, Frithz A, Stenlund K. *Malassezia furfur* in infantile seborrheic dermatitis. *Pediatr Dermatol*. 1997;14(6):423-425.
16. Mimouni K, Mukamel M, Zeharia A, Mimouni M. Prognosis of infantile seborrheic dermatitis. *J Pediatr*. 1995;127(5):744-746.
17. Taieb A, Legrain V, Palmier C, Lejean S, Six M, Maleville J. Topical ketoconazole for infantile seborrheic dermatitis. *Dermatologica*. 1990;181(1):26-32.
18. Cohen S. Should we treat infantile seborrheic dermatitis with topical antifungals or topical steroids? *Arch Dis Child*. 2004;89(3):288-289.
19. Brodell RT, Patel S, Venglarcik JS, Moses D, Gemmel D. The safety of ketoconazole shampoo for infantile seborrheic dermatitis. *Pediatr Dermatol*. 1998;15(5):406-407.
20. Zeharia A, Mimouni M, Fogel D. Treatment with bifonazole shampoo for scalp seborrhea in infants and young children. *Pediatr Dermatol*. 1996;13(2):151-153.